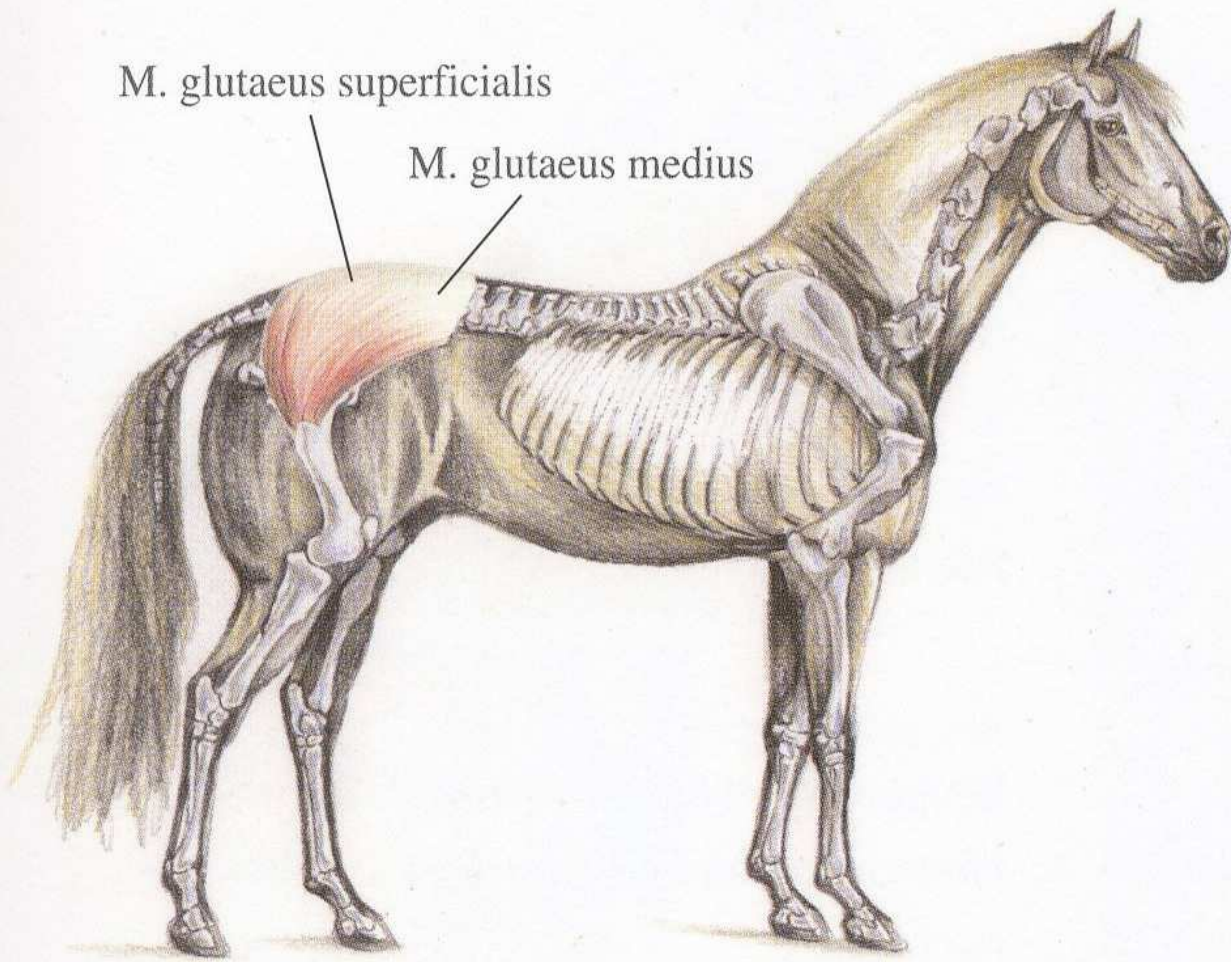


M. glutaeus superficialis

M. glutaeus medius



M. piriformis

M. adductor femoris

